

ORTHODONTIC TREATMENT OF A LOW ANGLE CLASS II MALOCCLUSION THAT REQUIRED AN ORTHODGNATHIC SUGICAL PROCEDURE — JOHN BILODEAU

INTRODUCTION

A common finding in a low angle Class II malocclusion is that the maxillary incisor is in correct position relative to the cranial base and the facial profile is normal or recessive. This case report shows one treatment approach to this type of problem.

HISTORY AND ETIOLOGY

The patient was a 31 year 11 month old white female with an unremarkable medical history. Dental history revealed prior orthodontic treatment and regular dental care. She had a Class II malocclusion with a straight and over closed facial profile. Her chief concerns were her “protruding teeth and facial appearance when smiling”. Primary etiology is believed to be heredity.

DIAGNOSIS

The facial photographs (Fig.1) demonstrate a straight and slightly over closed facial profile.

The dental casts (Fig. 2A, 2B) exhibit an Angle's Class II malocclusion with 7mm of overjet and 100% overbite. All third molars are missing. There is a deep curve of Spee.

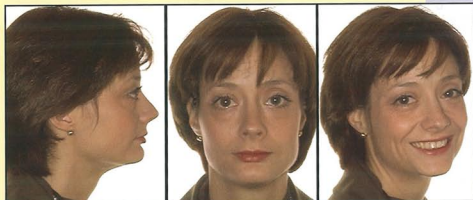

Fig. 1. Pretreatment facial photographs

The panoramic radiograph (Fig. 3) reveals no dental pathology. All teeth are present except the third molars.

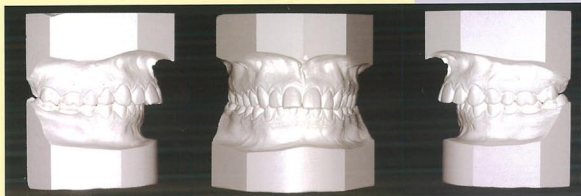

Fig. 2A. Pretreatment dental casts

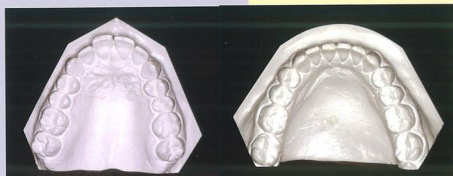

Fig. 2B. Pretreatment dental casts

measurement of 6mm reflects alveolar imbalance.

TREATMENT OBJECTIVES

1. Maintain a normal profile line to nose relationship and a normal Z angle²
2. Reduce overbite and overjet
3. Obtain normal canine and incisal guidance
4. Increase lower anterior facial height

TREATMENT ALTERNATIVES

1. Extract the maxillary 1st premolars and mandibular 2nd premolars to correct the overjet and overbite. This option could have a deleterious effect on the facial profile.
2. Extraction of only the maxillary right and left 1st premolars to correct the overbite and overjet. This option could collapse the upper lip.
3. Non extraction 10-2 orthodontic treatment. This option was considered but the amount of cooperation required was not appealing to the patient.
4. Non extraction treatment and a mandibular advancement with a genioplasty to increase lower facial height. This option would provide an ideal result.

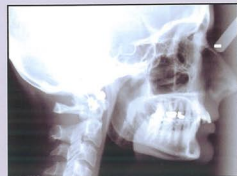

Fig. 4A. Pretreatment cephalometric radiograph

The cephalogram and its tracing (Figs. 4A, 4B) illustrate an ANB angle of 3°. The SNA angle of 77° confirms a slight maxillary deficiency. The FMA is 8°. The .86 facial height index of Horn¹ is a confirmation of an imbalance of anterior and posterior facial height. The IMPA angle of 92° reflects an acceptable inclination of the mandibular incisors. The Z angle² of 88° confirms a retruded soft tissue overlay, however, Wits^{3,4}

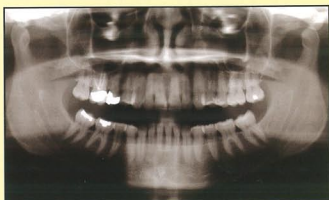

Fig. 3. Pretreatment panoramic radiograph

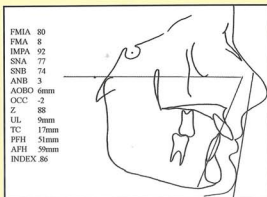


Fig. 4B. Pretreatment cephalometric tracing

TREATMENT PLAN

When orthodontic treatment without surgical correction is planned, the diagnosis is predicated on the pretreatment position and the desired final position of the mandibular incisors. Merrifield's total space analysis^{5,6} was used to determine space requirements.

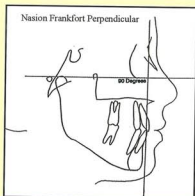


Fig. 5. McNamara's Nasion Frankfort Perpendicular

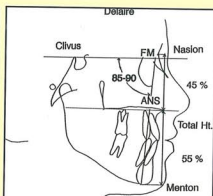


Fig. 6. Delaire Analysis

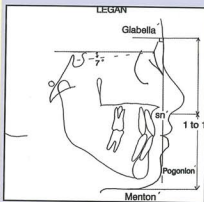


Fig. 7. Legan-Burstone analysis

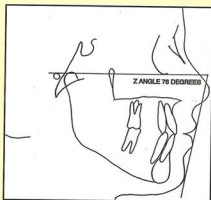


Fig. 8. Profile Line and Z angle

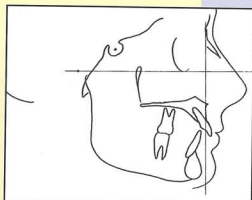


Fig. 9. Pretreatment McNamara tracing shows Point A and the Maxilla in correct position

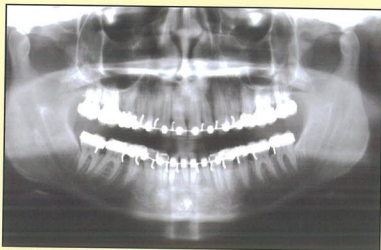

Fig. 10. Presurgical panoramic radiograph

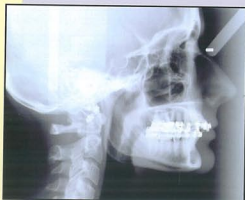

Fig. 11A. Presurgical cephalometric radiograph

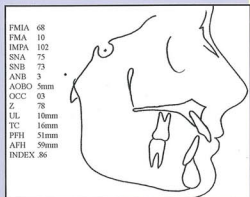


Fig. 11B. Pre surgical cephalometric tracing

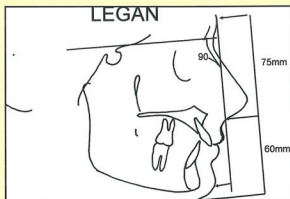


Fig. 12. Pre surgical Legan- Burstone soft tissue analysis

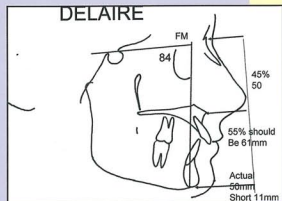


Fig. 13. Pre surgical Delaire Analysis

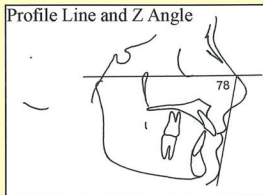


Fig. 14. Pre surgical profile line and Z angle would not be maintained unless a reduction genioplasty was part of the plan

When surgical intervention is also included as part of the treatment, several analyses are used as guidelines to position the jaw bones both vertically and horizontally in order to provide a pleasing and harmonious face.

McNamara's nasion Frankfort perpendicular⁷ was used as a guideline to determine the placement of the maxilla and the maxillary incisors in the horizontal plane. The maxilla should be positioned so point A closely approximates this line and the maxillary incisor is 5 mm plus or minus 2 mm anterior to this line (Fig. 5). The maxillary incisor should be placed at approximately 110° to the palatal plane.

The skeletal position of the mandible can be checked with the Delaire analysis⁸ using a line from FM point (frontal and maxillary bone intersection) connected to the posterior clinoid process and from this point to menton. This angular measurement should be 85° to 90° degrees. (Fig. 6) Also, with a line drawn perpendicular to this line, a vertical assessment can be made by measuring the upper facial height from nasion to ANS and lower facial height from ANS to menton. The distance between ANS and nasion should be 45% of the total facial height, and the measurement from ANS to menton along this line should be 55% of the total facial height. To determine the ideal facial height .45 can be divided into the nasion-ANS distance. This is the total "hard tissue" height that is ideal for a patient. This measurement gives guidelines as to whether to open or close a patient vertically.

In any surgical treatment plan, a soft tissue evaluation is necessary. Variations in the soft tissue that covers the face can produce misleading conclusions if diagnosis and treatment planning are based on skeletal measurements alone. With the Legan-Burstone⁹ soft tissue analysis the horizontal and vertical soft tissue of the mandible can be evaluated (Fig. 7). The SN line is reconstructed 7° upward from its original position. A perpendicular is drawn from soft tissue glabella to this line. Soft tissue pogonion should closely approximate this line. Vertical soft tissue proportions

can be checked by drawing a line perpendicular from glabella to soft tissue nasal point and from subnasal point to menton. The ratio of this distance should be 1 to 1. Another helpful soft tissue evaluation is Merrifield's Z angle² and the interrelationship of the profile line to the middle of the nose. The profile line should intersect the

nose at the anterior aspect of the nares and when measured to Frankfort horizontal, should make a Z angle of 78° (Fig. 8).

Since the maxillary incisors and point A were almost in correct position according to Mc Namara (Fig. 9) a decision was made to treat the dentition without premolar extractions in preparation for mandibular advancement surgery. This approach would not retract the maxillary incisors and would reduce the curve of Spee.

TREATMENT PROGRESS

All teeth were sequentially banded or bonded with .022 standard nontorqued nonangulated edgewise brackets. The 10-2 non extraction syllabus was followed¹⁰. As treatment progressed, 'black triangles'^{11,12,13} became noticeable in the maxillary arch. The maxillary anterior teeth were interproximally recontoured to move the contacts towards the gingiva. As this procedure was being accomplished, it was necessary to rebond several anterior teeth and to make

closing arches to further close maxillary space created by reshaping the incisors.

Dental casts were made at every appointment until the teeth could be hand articulated in Class I centric occlusion. At this juncture progress records were taken.

The presurgical panoramic radiograph (Fig. 10) shows all roots are parallel and the curve of Spee has been reduced.

The presurgical cephalometric radiograph and its tracing (Fig. 11A, Fig. 11B) show an IMPA angle of 102°. The FMA angle increased to 10°. The Z angle was 78° with a less than ideal profile line to nose to nose relationship.

The soft tissue analysis of Legan and Burstone (Fig. 12) and the Delaire analysis (Fig. 13) showed that vertical



Fig. 15. Posttreatment facial photographs

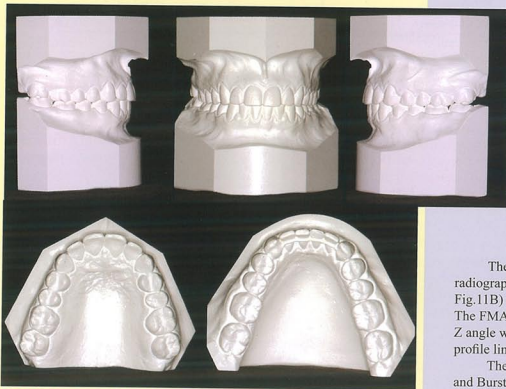

Fig. 16. Posttreatment dental casts

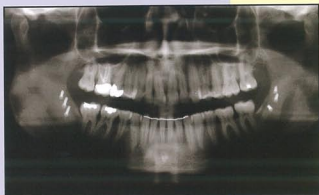

Fig. 17. Posttreatment panoramic radiograph

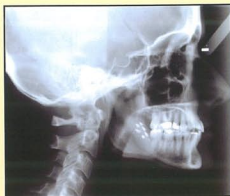

Fig. 18A. Posttreatment cephalometric radiograph

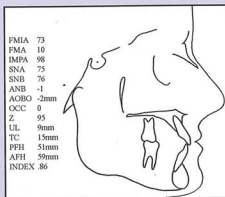


Fig. 18B. Posttreatment cephalometric tracing

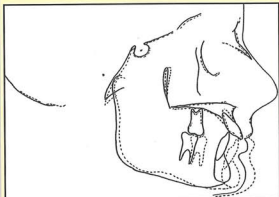


Fig. 19. Composite tracings

height needed to be increased and the mandible advanced. The Z angle was 78° and profile line to nose was ideal according to Merrifield (Fig. 14) and would not be maintained unless a reduction genioplasty was part of the surgical plan. This would take away the influence of the chin,

further increase facial height, and provide an ideal profile line to nose relationship. The patient would not agree to the genioplasty because her insurance would not approve it.

TREATMENT RESULTS

- The posttreatment facial photographs (Fig. 15) illustrate a marked improvement in the facial profile on smiling. The profile line does not intersect the middle of the nose. The chin projection is strong but not objectionable.
- The posttreatment dental casts (Fig. 16) exhibit a Class I occlusion with normal overjet, overbite, canine and incisal guidance.
- The posttreatment panoramic radiograph (Fig. 17) exhibits no pathology.
- The posttreatment cephalometric radiograph and its tracing (Fig. 18A, Fig. 18B) illustrates the changes that were achieved with treatment. The mandibular incisors were uprighted over basal bone to an IMPA angle of 98°. The FMA angle increased to 10°.
- The composite cephalometric tracings illustrate the changes achieved (Fig. 19).
- A Maxillary Hawley and a lower bonded retainer were placed. Total treatment time was 17 months.

REFERENCES

1. Horn AJ. Facial height index. *Am J Orthod* 1992; 101:180-6.
2. Merrifield LL. The profile line as an aid in critically evaluating facial esthetics. *Am J Orthod* 1966; 52, 11:804-22.
3. Jacobson A. The "Wits" appraisal of jaw disharmony. *Am J Orthod* 1967 (2):125-138, 1975(volume 67, number 2, Feb. 1975
4. Jacobson A. "Wits appraisal" in Radiographic Cephalometry. Quintessence Publishing Co, Inc :1195:97-112.
5. Merrifield LL. Differential diagnosis with total space analysis. *J Charles Tweed Foundation* 1978; 6:10-15.
6. Vaden JL, Dale JG, Klontz HA. The Tweed-Merrifield philosophy. In: Graber TM, Vanarsdall RL, eds. *Orthodontics: current principles and techniques*. St. Louis: CV Mosby, 1994:627-84.
7. McNamara JA. A method of cephalometric evaluation. *Am J Orthod* 1984; 86:49-69.
8. Delaire J, Schendel SA, Tulasne JF. An architectural and structural craniofacial analysis: a new lateral cephalometric analysis. *J Oral Surg* 1981; 52:226-38.
9. Legan HL, Burstone CJ. Soft tissue cephalometric analysis for orthognathic surgery. *J Oral Surg* 1980; 38:744-51.
10. Merrifield LL. Edgewise sequential directional force technology. *J Charles Tweed Found* 1986; 14:22-37.
11. Burke S, Dent IV, Burch SG, Tetz, JA. Incidence and size of pretreatment overlay and post treatment gingival embrasure space between maxillary central incisors. *Am J Orthod Dentofac Orthop* 1994; 105:506-11.
12. Kokich, VG. Esthetics: The Orthodontic-Periodontic Restorative Connection. *Semin Orthod* 1996; 2:21-30.
13. Kokich VG, Mathews DP. Managing treatment for the orthodontic patient with pseudo dental problems. *Semin Orthod* 1997; 3:21-38.



