

# AMERICAN BOARD OF ORTHODONTICS CASE REPORT

## *An American Board of Orthodontics case report*

**John E. Bilodeau, DDS, MS**

*Springfield, Va.*

[This case report was presented to the American Board of Orthodontics in partial fulfillment of the requirements for the certification process conducted by the Board.] (*Am J Orthod Dentofac Orthop* 1997;111:487-91.)

### **CASE REPORT**

#### **History and General Clinical Background**

The patient was a normally developed boy who was 12 years, 10 months of age at the time of the initial records. He had a severe Class II malocclusion with a deep curve of Spee, a 10 mm overjet, and facial imbalance. The chief concerns expressed by the family were his protruding teeth and his facial appearance.

#### **DIAGNOSIS**

The facial photographs (Fig. 1) show severe facial distortion and lip fullness. The patient was not able to close his lips without mentalis strain.

The dental casts (Fig. 2) show a Class II molar and canine relationship with the mandibular incisors impinging on the palate. The overjet measured 10 mm. The mandibular arch was constricted in the premolar area. The maxillary first premolars were in buccal crossbite.

The panoramic radiograph (Fig. 3) revealed a full complement of teeth with space limited for the eruption of the third molars.

The cephalometric radiograph and its tracing (Fig. 4) illustrated an ANB angle of 7°. The SNB angle was 79°. The SNA angle of 86° suggests a protrusive maxilla. The

FMA was a low 21°. The facial height index of Horn<sup>1</sup> was 0.78. The IMPA angle of 103° confirmed procumbent mandibular incisors. The Z angle was 56°. The nasiolabial angle was obtuse.

#### **TREATMENT OBJECTIVES**

1. Correct the Class II dental relationship.
2. Reduce the overbite and the overjet.
3. Obtain a normal profile line relationship and Z angle with upper lip curl.
4. Obtain normal canine and incisal guidance.
5. Correct the crossbite in the premolar areas.

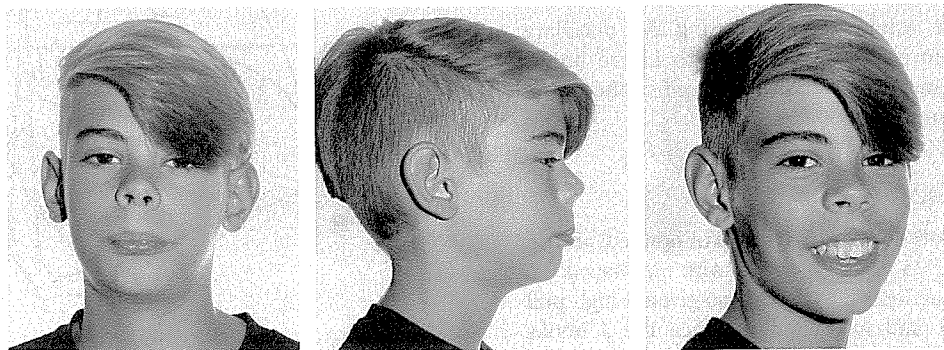
Attainment of these treatment objectives was dependent on the proper selection of extractions, mandibular anchorage control, and mechanics.

#### **TREATMENT PLAN**

The maxillary first premolars and the mandibular second premolars were selected for extraction. The primary reason for the extraction choices was that maximum retraction of the maxillary anterior teeth and minimal retraction of the mandibular anterior teeth was needed. The lower second premolar extraction would also allow the first molars to be moved mesially to correct the Class II molar relationship. Maxillary first premolar removal would provide space to retract the maxillary anterior teeth maximally and to move point A distally.

Reprint requests to: Dr. John E. Bilodeau, 6116 Rolling Rd., Springfield, VA 22152.

Copyright © 1997 by the American Association of Orthodontists.  
0889-5406/97/\$5.00 + 0 8/4/68894



**Fig. 1.** Pretreatment facial photographs.

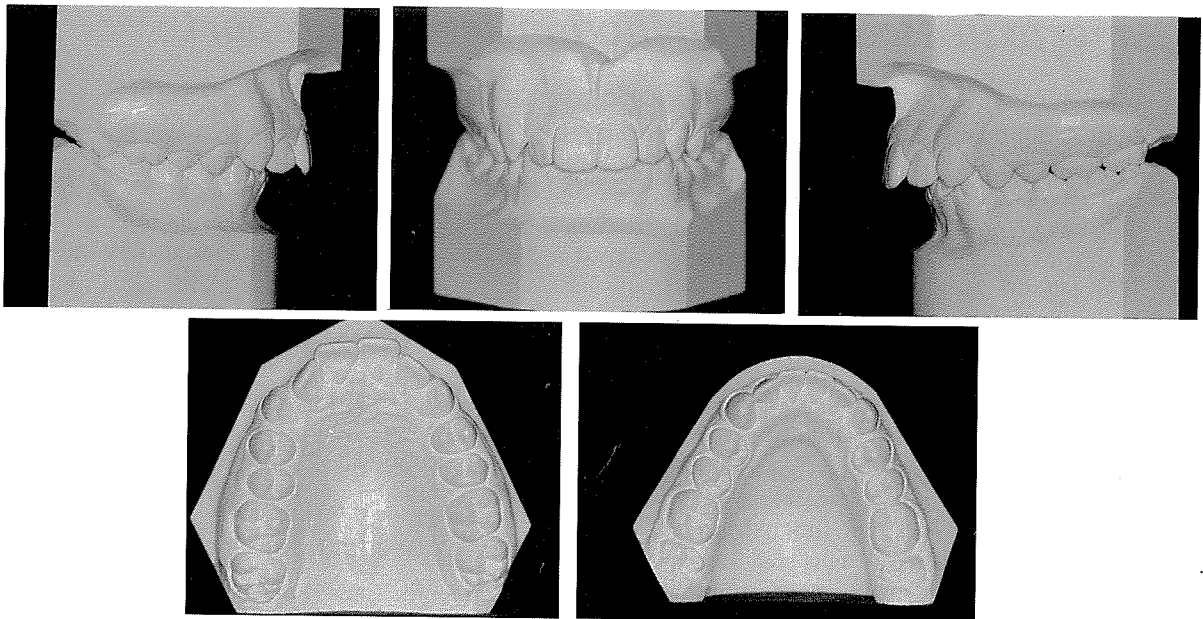


Fig. 2. Pretreatment dental casts.

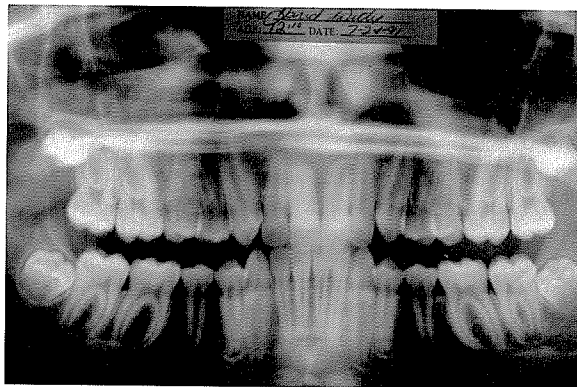
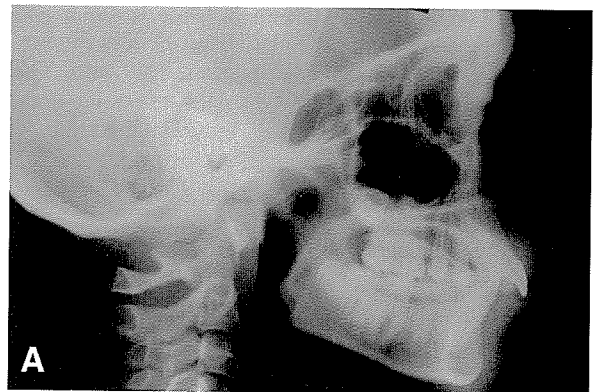


Fig. 3. Pretreatment panoramic radiograph.

Extreme care would be used during the maxillary anterior retraction phase of treatment to insure bodily retraction of the maxillary anterior segment so the nasio-labial angle was not adversely affected.

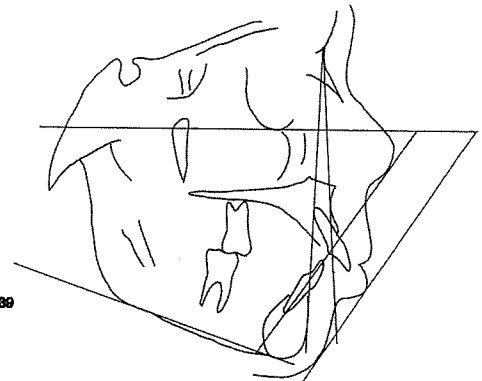
**TREATMENT PROGRESS**

All the maxillary teeth were banded or bonded, and an initial 0.0175 × 0.025 rectangular arch wire was placed. To begin canine retraction, the patient was given a high-pull J hook headgear and instructed to place the J hooks directly against the canine brackets. The patient was instructed to wear the headgear 10 hours a day. At the



A

SNA 86  
SNB 79  
ANB 7  
WITS +3  
FMA 21  
IMPA 103  
FMIA 56  
PFHT 47  
AFHT 60  
INDEX .78  
1 TO 1 ANGLE 139  
Z ANGLE 56



B

Fig. 4. A, Pretreatment cephalometric radiograph. B, Pretreatment cephalometric tracing and values.

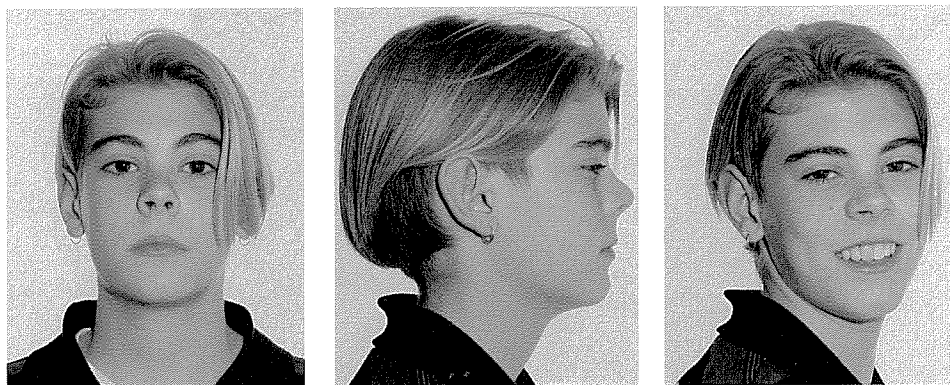


Fig. 5. Posttreatment facial photographs.

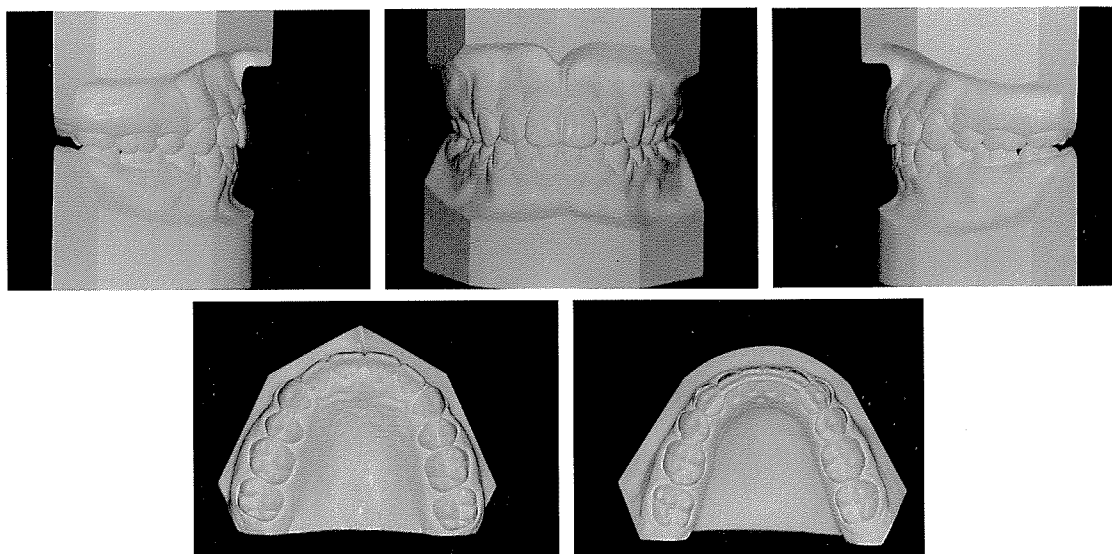


Fig. 6. Posttreatment dental casts.

next appointment, the mandibular canines, first premolars, and first molars were banded and an initial  $0.0175 \times 0.025$  mandibular arch wire with  $10^\circ$  of terminal molar tip was inserted. A high-pull J hook headgear was attached to hooks soldered mesial to the mandibular canine brackets. An elastic chain was stretched from the terminal molars in both arches to the canine brackets. At successive appointments, the mandibular incisors were bonded and both arches were retied. When the mandibular extraction space was closed, a  $0.019 \times 0.025$  arch wire was fabricated and mandibular anchorage was prepared. After sufficient mandibular anchorage had been prepared, a maxillary  $0.020 \times 0.025$  closing loop was fabricated and the anterior teeth were retracted with a combination of closing loop force and Class II elastic force. The Class II elastics were

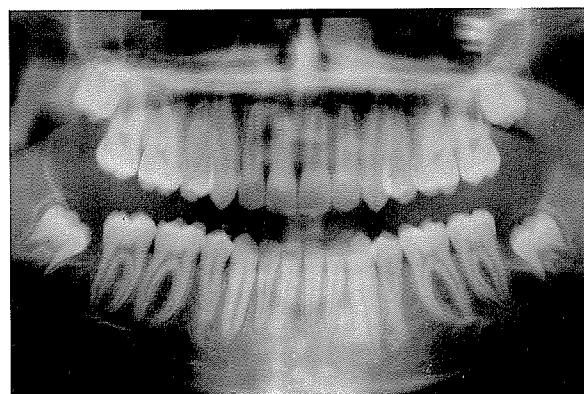
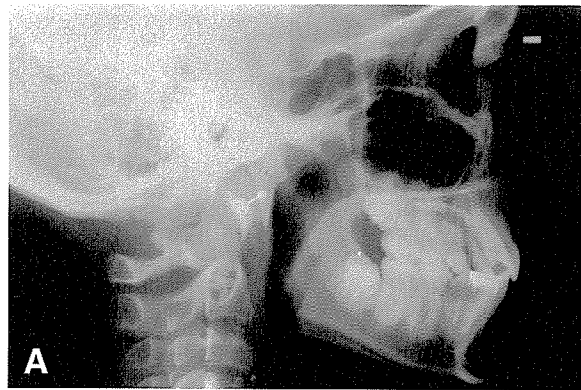
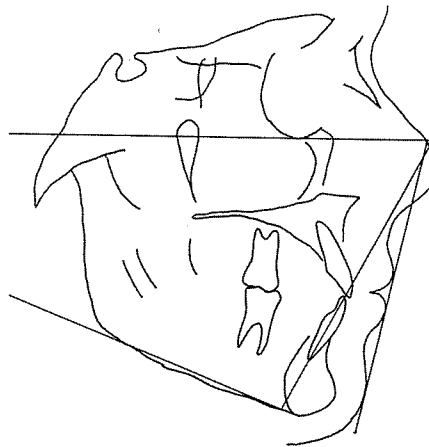


Fig. 7. Posttreatment panoramic radiograph.



SNA 81  
SNB 79  
ANB 2  
WITS -2  
FMA 21  
IMPA 96  
FMIA 63  
PFHT 52  
AFHT 64  
INDEX .81  
1 TO 1 ANGLE 132  
Z ANGLE 77



**B**

Fig. 8. A, Posttreatment cephalometric radiograph. B, Posttreatment cephalometric tracing and values.

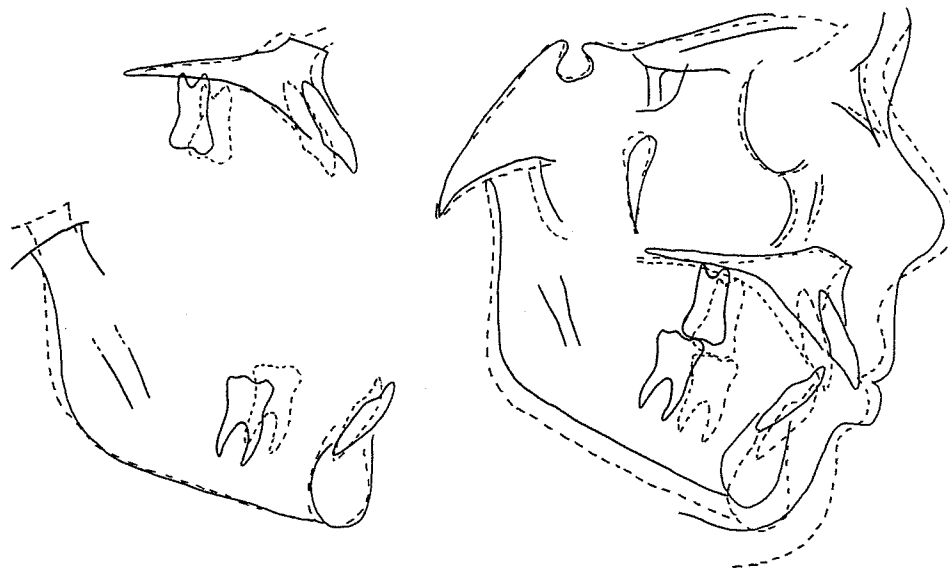


Fig. 9. Superimposition of the pretreatment and posttreatment cephalometric tracings.

supported with vertical elastics and a high-pull J hook headgear attached to the arch wire on hooks soldered between the maxillary central and lateral incisors. After the maxillary space was closed, an ideal maxillary  $0.021 \times 0.025$  arch wire was fabricated. The occlusion was detailed and finished with Class II elastics. Total treatment time was 26 months.

#### TREATMENT RESULTS

The facial photographs (Fig. 5) show a marked improvement in the facial profile. Mentalis strain has been eliminated.

The posttreatment dental casts (Fig. 6) show a Class I occlusion with normal overjet and overbite.

The panoramic radiograph (Fig. 7) confirms that all roots are parallel and that the extraction spaces are closed. There is no disease or root resorption present.

The final cephalometric radiograph and its tracing (Fig. 8) reveal that point A has been moved distally. The SNA value is  $81^\circ$ . The SNB angle is still  $79^\circ$ . The facial height index increased to 0.81, indicating a favorable mandibular response. The Z angle is  $77^\circ$  and the profile line to nose relationship is normal. Because of the high facial height index, mandibular uprighting was adjusted to an IMPA of  $96^\circ$ .

Superimposition (Fig. 9) of the pretreatment and posttreatment cephalometric tracings shows good mandibular response and illustrates the intrusion and retraction of the maxillary incisors.

#### REFERENCES

1. Horn AJ. Facial height index. *Am J Orthod* 1992;101:180-6.

#### AAO MEETING CALENDAR

- 1998 — Dallas, Texas, May 16 to 20, Dallas Convention Center
- 1999 — San Diego, Calif., May 15 to 19, San Diego Convention Center
- 2000 — Chicago, Ill., April 29 to May 3, McCormick Place Convention Center  
(5th IOC and 2nd Meeting of WFO)
- 2001 — Toronto, Ontario, Canada, May 5 to 9, Toronto Convention Center
- 2002 — Baltimore, Md., April 20 to 24, Baltimore Convention Center
- 2003 — Hawaiian Islands, May 2 to 9, Hawaii Convention Center
- 2004 — Orlando, Fla., May 1 to 5, Orlando Convention Center